

Acute STEMI with LAD Lesion Treated with Percutaneous Coronary Intervention (PCI) and SuperSaturated Oxygen (SSO₂) Therapy at Baystate Medical Heart & Vascular Center in Springfield, Massachusetts

by Amir Lotfi, M.D.

A 63-year old male arrived at Baystate Medical Heart & Vascular Center with suspected myocardial infarction. The patient had developed substernal chest pain 5 hours prior and contacted EMS. EMS found the patient pale and diaphoretic and a 12-lead ECG confirmed anterior ST-elevation myocardial infarction (STEMI). The patient's blood pressure was 124/80 and he had been taking daily aspirin of 81 mg. No significant medical history was reported.

The patient received a single dose each of heparin (4,000 mg) and ticagrelor (180 mg) by mouth and was transferred to the cardiac catheterization lab. Coronary angiography was performed via right common femoral artery access and bivalirudin bolus and drip initiated. Angiography indicated a complete left anterior descending (LAD) blockage (Figure 1). Following manual thrombectomy, a 3.5 x 18 mm drug eluting stent was deployed and post-dilated with a 3.5 x 12 mm non-compliant balloon. No residual stenosis was noted via final angiography. (Figure 2). Total time from symptom onset to intervention time was <6 hours.

SSO₂ Therapy

Following successful PCI the patient was considered for SuperSaturated Oxygen (SSO₂) Therapy and qualified for inclusion in the IC-HOT Study (TherOx, Inc) per designated protocol. Existing femoral access was utilized for therapy infusion and the patient remained in the cath lab throughout the infusion time. Following sixty minutes of therapy the patient was transferred to the cardiac care unit. The patient was discharged 3 days post-procedure.

Day Five Evaluation

MRI imaging was conducted at day five post-procedure and revealed end diastolic volume (EDV) of 130 ml and end systolic volume (ESV) of 68 ml. Ejection fraction

was measured at 48%. A moderate-to-large LAD injury with heterogeneous delayed hyperenhancement signal abnormality was observed.

Day 30 Evaluation

Per IC-HOT protocol, a follow-up visit was conducted at 30 days. EDV and ESV were measured via MRI noted at 134 ml and 49 ml, respectively. The abnormal LV myocardium hyperenhancement seen at day five had visibly resolved. Ejection fraction showed an improvement at 63% vs 48% measured at day five.

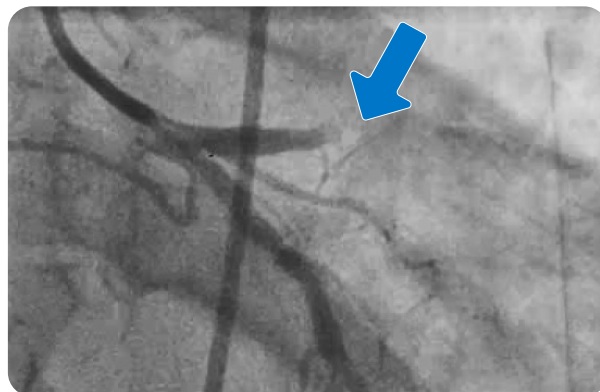

Figure 1. Pre-PCI Angiography of LAD

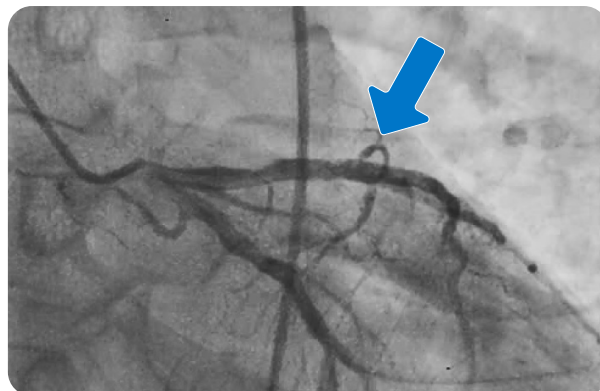


Figure 2. Post-PCI Angiography of LAD

Background

Acute Myocardial Infarction (AMI) is a leading cause of death in the United States, affecting roughly 790,000 patients each year¹. Even with timely recognition and prompt restoration of coronary blood flow using PCI or pharmacological treatments, microvascular damage and tissue necrosis still persist and may lead to heart failure, reinfarction, and death.

SSO₂ Therapy has been proven through a series of FDA-sanctioned, IDE trials – AMIHOT I², AMIHOT II³, and IC-HOT⁴ – as safe and effective in significantly reducing infarct size for patients with anterior LAD STEMI presenting within 6 hours of symptoms. Infarct size reduction is associated with long-term reductions in mortality and heart failure. For qualifying anterior LAD STEMI patients, SSO₂ Therapy should be considered as part of STEMI treatment protocol in optimizing infarct size reduction, improving microvascular flow and preserving left ventricle function.

SSO₂ Therapy

For anterior LAD STEMI patients who receive successful PCI and stenting within 6 hours of symptom onset, SSO₂ Therapy is a one-time, 60-minute infusion performed in the cardiac catheterization laboratory immediately following successful PCI. Autologous arterial blood is mixed with oxygen-rich saline in a low-priming volume (50 ml) blood loop to achieve hyperoxic levels of oxygen (pO₂=1000mmHg). The superoxygenated infusate is returned to the patient via a 5F angiographic-style delivery catheter placed in the ostium of the LMCA (Figure 3). The hyperoxic level of dissolved oxygen (7-10x normal) creates a large concentration gradient for oxygen to diffuse into ischemic tissue even when blood flow is compromised. Since SSO₂ Therapy is an adjunctive treatment performed after successful PCI, it complements the current standard of care, without delays in treatment or door-to-balloon time.

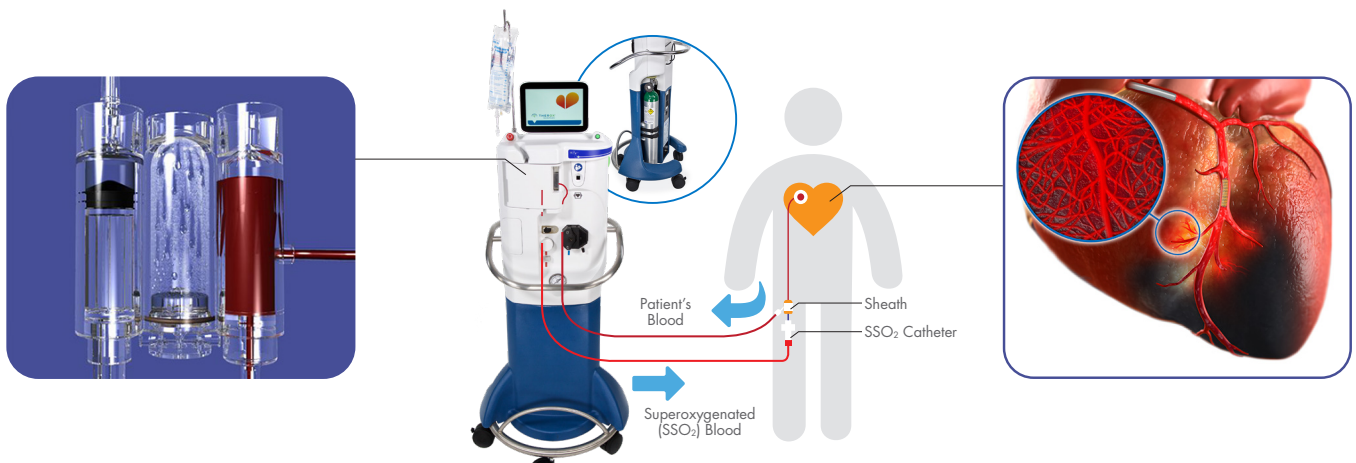


Figure 3. SSO₂ Therapy patient connections and delivery

Indications For Use: The TherOx DownStream System is indicated for the preparation and delivery of SuperSaturated Oxygen Therapy (SSO₂ Therapy) to targeted ischemic regions perfused by the patient's left anterior descending coronary artery immediately following revascularization by means of percutaneous coronary intervention (PCI) that has been completed within 6 hours after the onset of anterior acute myocardial infarction (AMI) symptoms caused by a left anterior descending artery infarct lesion.

Caution: Federal (USA) Law restricts this device to the sale by or on the order of a physician.

¹ American Heart Association. Heart Disease and Stroke Statistics, 2017 At-A-Glance.

² O'Neill WW, et al. Acute Myocardial Infarction With Hyperoxic Therapy (AMIHOT), A Prospective, Randomized Trial of Intracoronary Hyperoxic Reperfusion After Percutaneous Coronary Intervention. *Jour of Am Coll Cardiol*. 2007;50; No.5. 397-405.

³ Stone GW, et al. Effect of supersaturated oxygen delivery on infarct size after percutaneous coronary intervention in acute myocardial infarction. *Circ Cardivasc Interv*; 2; 366-375. Sep 2009.

⁴ David SW, et al. Evaluation of intracoronary hyperoxic oxygen therapy in acute anterior myocardial infarction: The IC-HOT study. *Catheter Cardiovasc Interv*. 2018;1-9.

ZOLL Medical Corporation • Chelmsford, MA, USA • 800-348-9011 • www.zoll.com

© 2020 ZOLL Medical Corporation. All rights reserved. TherOx and ZOLL are trademarks or registered trademarks of ZOLL Medical Corporation in the United States and/or other countries. All other trademarks are the property of their respective owners.

MCN HP 2001 0370
30155C

ZOLL